Medicine®

OBSERVATIONAL STUDY

OPEN

Laparoscopic Low Anterior Resection and Eversion Technique Combined With a Nondog Ear Anastomosis for Mid- and Distal Rectal Neoplasms

A Preliminary and Feasibility Study

Changhua Zhuo, MD, PhD, Lei Liang, MD, PhD, Mingang Ying, MD, Qingguo Li, MD, PhD, Dawei Li, MD, PhD, Yiwei Li, MD, PhD, Junjie Peng, MD, PhD, Liyong Huang, MD, PhD, Sanjun Cai, MD, and Xinxiang Li, MD

Abstract: The transanal eversion and prolapsing technique is a well-established procedure, and can ensure an adequate distal margin for patients with low rectal neoplasms. Potential leakage risks, however, are associated with bilateral dog ear formation, which results from traditional double-stapling anastomosis. The authors determined the feasibility of combining these techniques with a commercial stapling set to achieve a nondog ear (end-to-end) anastomosis for patients with mid- and distal rectal neoplasms.

Patients with early-stage (c/ycT1–2N0), mid- to distal rectal neoplasms and good anal sphincter function were included in this study. Laparoscopic low anterior resection was performed with a standard total mesorectal excision technique downward to the pelvic floor as low as possible. The bowel was resected proximal to the lesion with an endoscopic linear stapler. An anvil was inserted extracorporeally into the proximal colon via an extended working pore. The distal rectum coupled with the lesion was prolapsed and everted out of the anus. The neoplasm was resected with a sufficient margin above the dentate line under direct sight. A transrectal anastomosis without dog ears was performed intracorporeally to reconstitute the continuity of the bowel.

Eleven cases, 6 male and 5 female patients, were included in this study. The mean operative time was 191 (129–292) minutes. The mean blood loss was 110 (30–300) mL. The median distal margin distance from the lower edge of the lesion to the dentate line was 1.5 (0.5–2.5) cm. All the resection margins were negative. Most patients experienced uneventful postoperative recoveries. No patient had anastomotic leak. Most patients had an acceptable stool frequency after loop ileostomy closure.

Our preliminary data demonstrated the safety and feasibility of achieving a sound anastomosis without risking potential anastomotic leakage because of dog ear formation.

(*Medicine* 94(50):e2285)

Abbreviations: ASA = the American Society of Anesthesiologists, DST = double-stapling technique, Lap LAR = laparoscopic low anterior resection.

INTRODUCTION

At the time of this writing, local excisions, including traditional transanal resection, endoscopic submucosal dissection, and transanal endoscopic microsurgery, are established approaches for selected patients with early-stage distal rectal cancer. Local excisions, however, should only be offered to patients with T1N0 lesions with favorable clinical and pathologic features.[1] Owing to potential lymph node metastases (incidence range: 0%–3% for T1 sm1, up to 15% for T1 sm2–3 and up to 25% for T2 tumors),[2–5] rectal resection with total mesorectal excision (TME) is the current gold standard for the treatment of mid- and distal rectal neoplasms.[1,6,7] This technique offers the oncologic benefit of reduced local recurrence and increased 5-year survival rates when combined with neoadjuvant radiation therapy.[8–10]

Laparoscopic colorectal surgery has progressed steadily since Jacobs' first introduction in 1990.[11] Laparoscopic low anterior resection (Lap LAR) is an ideal, minimally invasive surgical procedure for mid- and distal rectal cancer. Compared with open surgery, the laparoscopic approach has similar surgical safety, resection completeness, resection margins, and improved in-hospital recovery.[12–15] Recent studies of patients with nonlocally advanced rectal cancer have confirmed that both approaches have similar oncologic results, including local recurrence, disease-free survival and overall survival, after at least 3 years and up to 10 years.[16–18]

The prolapsing procedure for rectal cancer is also known as the eversion technique. It was first performed by Maunsel in 1892 (initially published in Lancet 1892: 2: 473–476).[19] There are several classic modifications of this procedure, that is, the Welch, Bacon, and Parks procedures.[20] Most, however, are applicable to lesions within the middle-third of the rectum. In an

Editor: Wafi Attaallah.
Received: July 7, 2015; revised: November 5, 2015; accepted: November 17, 2015.
Department of Colorectal Surgery, Fudan University Shanghai Cancer Center (CZ, LL, QL, DL, YL, JP, LH, SC, XL); Department of Oncology, Shanghai Medical College, Fudan University, Shanghai (CZ, LL, QL, DL, YL, JP, LH, SC, XL); and Department of Surgical Oncology, Fujian Provincial Cancer Hospital, Teaching Hospital of Fujian Medical University, Fuzhou, China (CZ, MY).
Correspondence: Xinxiang Li, MD, Department of Colorectal Surgery, Fudan University Shanghai Cancer Center, 270 Dong-An Road, Shanghai 200032, China (e-mail: lxx1149@163.com).
CZ and LL have contributed equally to this work.
This research was supported by grants from the Medical Innovation Program of Fujian Province (No. 2015-CXB-6 to Changhua Zhuo), the National Natural Science Foundation of China (No. 51377024 to Xinxiang Li), and the Research Project of Shanghai Science and Technology Commission (No.13JC1407202 and No. 15411968100 to Xinxiang Li).
The funders had no role in the study design, data collection and analysis, decision to publish, or preparation of the manuscript. The authors declare that they have no conflict of interest.
Copyright © 2015 Wolters Kluwer Health, Inc. All rights reserved.
This is an open access article distributed under the terms of the Creative Commons Attribution-NonCommercial-ShareAlike 4.0 License, which allows others to remix, tweak, and build upon the work non-commercially, as long as the author is credited and the new creations are licensed under the identical terms.
ISSN: 0025-7974
DOI: 10.1097/MD.0000000000002285

era without staplers, considerable postoperative morbidity and mortality occurred. As a consequence of modern surgical and anesthetic advancements and the introduction of the circular stapler for colorectal anastomoses, the number of sphincter-saving operations for patients with rectal cancer has increased greatly.[21,22] More advances were achieved with the introduction of the double-stapling technique (DST).[23–25]

Double-stapling technique facilitates the feasibility of performing a sphincter-saving operation intracorporeally and laparoscopically.[26–29] Moreover, with the introduction of inter-sphincteric resection,[30–32] the possibility of sphincter preservation for patients with ultralow rectal cancer[33,34] has increased steadily. Double-stapling technique, however, is inevitably associated with bilateral intersecting margins at the distal rectal stump (the so-called dog ears). The dog ears have been reported to be the weak spots and are associated with potential anastomotic leaks.[24,35]

In this preliminary study, we investigated the feasibility of a perineal staple set to achieve a nondog ear (end-to-end) anastomosis with a combined Lap LAR and eversion technique to treat mid- and distal rectal neoplasms. Our primary objectives were to report our technical compliance, surgical safety, and early postoperative outcomes.

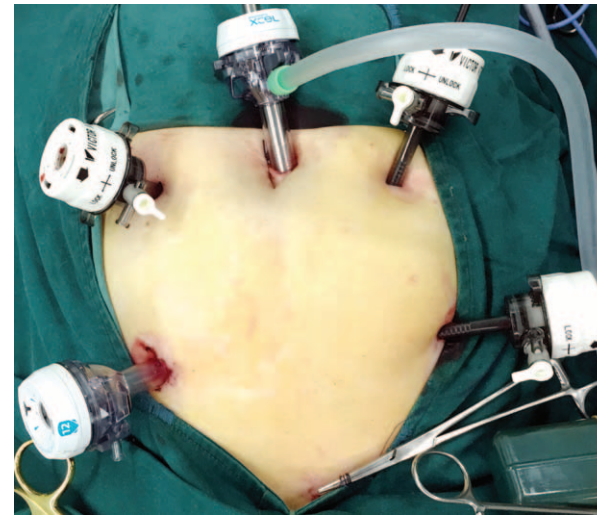

FIGURE 1. Five working ports were selected for the laparoscopic procedure. The bottom of the image presents the patient's caudal side. For a female patient, uterus hanging may be recommended. This can be fulfilled by placement of a 2–0 Prolene suture on the uterus. The stitch was then introduced outside the abdominal wall and fixed with adequate tension.

PATIENTS AND METHODS

Patients

A total of 11 consecutive patients with rectal cancer were documented. All patients were surgically treated by 1 surgical team (Xinxiang Li, MD) between June 2014 and May 2015. Patients with nonlocally advanced rectal cancer (cT1–2N0 or ycT1–2N0), good anal sphincter function (Wexner continence score <4), small tumor (maximum diameter <4 cm, and <1/2 circumference), and mid- and distal tumor locations (3–8 cm above the dentate line) were included in this study. Patients with recurrent disease, previous large open surgery with severe abdominopelvic sticks, inflammatory bowel disease, or familial adenomatous polyposis were excluded. Written informed consent was obtained from all patients, and the study protocol was approved by the Medical Ethics Committee of Fudan University Shanghai Cancer Center.

Operative Technique

Our technical procedure included the 4 following main parts: transabdominal Lap LAR with TME; preparation of the proximal end of the colon with purse string; transanal specimen extraction, transection, and stapler preparation of the distal end; and transanal colorectal anastomosis.

The patient was placed supine in the modified lithotomy position, and 5 ports were inserted (Figure 1). The Trendelenburg position was used following abdominopelvic exploration. At the iliac trigone, the medial mesenteric attachments were incised using an ultrasonic activated scalper (Harmonic®, Johnson & Johnson, NJ), and the superior hypogastric nerve plexus was identified and preserved. Proximal lymph node dissection was performed at the origin of the superior rectal artery. The superior rectal artery was dissected and transected following the application of Hem-o-Lock clips (Teleflex Inc., USA). The mesorectum was separated with the TME technique, which is similar to previously described reports.[28,36] The mesentery of the sigmoid colon was manipulated as little as possible. Toldt fusion fascia was moved posteriorly, and the gonadal vessels and ureters were preserved. The retrorectal space was entered, and the separation was continued to the ''holy plane'' extending to the rectosacral ligament. The right and left lateral attachments of the sigmoid colon were incised, and the sigmoid colon and rectum were mobilized. Posteriorly, dissection of the presacral space was performed from right to left and proceeded distally into the pelvis. Dissection of the anterior rectum was initiated by exposing Denonvilliers fascia with identification of the vaginal wall or seminal vesicles. Dissection was extended distally to expose the levator ani muscle. Lateral, posterior and anterior levels of dissection were checked to complete the circumferential dissection to the pelvic floor as low as possible (Figure 2).

The colon (10 cm proximal to the lesion) was transected laparoscopically using an endoscopic linear cutter (Ethicon® ET60a, Johnson & Johnson, NJ). The proximal colon was extracted through a small incision of 3 to 4 cm extended from the bottom-right pore, which was also used as the site of loop

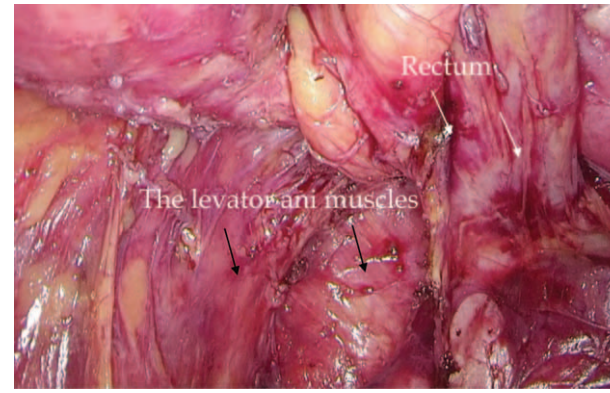

FIGURE 2. Dissection of the rectum. The rectum (white arrows) was dissected with the TME approach and proceeded circumferentially into the pelvic floor as distal as possible. The levator ani muscles were clearly displayed (black arrows).

Copyright © 2015 Wolters Kluwer Health, Inc. All rights reserved.

FIGURE 3. The distal rectum was everted and pulled outside the anus. The inner mucosa and the lesion were everted. The distance from the lower edge of the lesion to the dentate line was determined under direct vision.

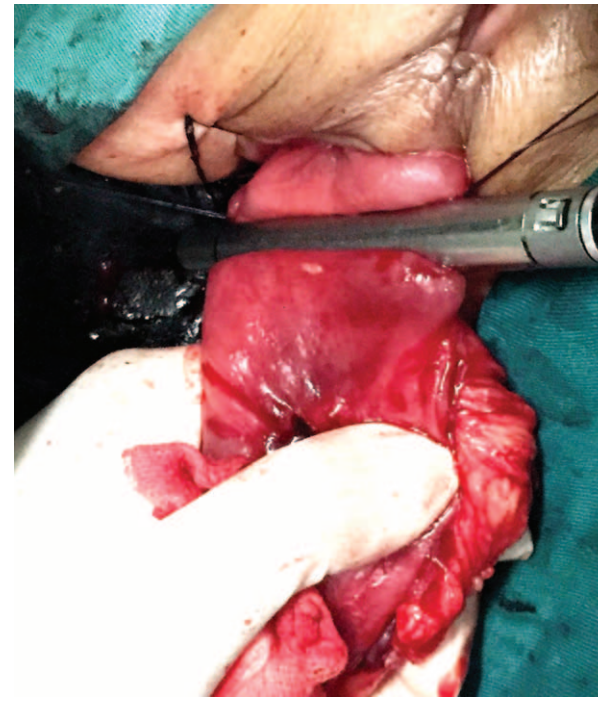

FIGURE 4. Transection of the rectum. This was performed using another firing of a linear cutter under direct vision after an adequate distal margin was confirmed.

ileostomy (LI) formation. An extra 5 to 10 cm of proximal colon was resected under direct vision to ensure a safe proximal margin. An anvil from a 29- or 33-mm circular stapler (CSC-29 or CSC33, KOL®, Touchstone International, Suzhou, China) was secured to the colon with a purse string suture. Then, the proximal colon was returned, followed by closure of the abdominal wall and re-establishment of the pneumoperitoneum.

The rectum was irrigated with Betadine solution, and the anus was gently distended digitally by an assistant surgeon. A grasping forcep was slowly inserted through the anus, and the stump of the distal rectum was grasped securely with laparoscopic guidance. Although withdrawing the forcep, the distal rectal segment accompanied by the rectal neoplasm was everted gradually and pulled gently outside of the anus with the inner mucosa everted (Figure 3). The resection line (1–2 cm distal to the lower edge of the lesion) was plotted under direct vision. Transection of the rectum was performed with another firing of the same linear cutting stapler (mentioned above; Figure 4). The specimen was carefully inspected to ensure an adequate distal margin (Figure 5). Two 2–0 Prolene sutures (Ethicon®, Johnson & Johnson, NJ were secured on the both extremities of the resection line, which was created by the second linear cutter. The tails of the stitches were introduced through the windows (both side of the stapler), and the rectal stump including the suture line (dog ears) was completely loaded into the cartridge of the stapler (Figure 6).

The distal rectum was returned gently to the pelvis through the anus. Intracorporeally, the anvil and center rod of the stapler were connected, the stapler was fired, and an end-to-end anastomosis was performed with laparoscopic guidance (Figure 7). The doughnuts were inspected carefully, and a routine transanal air leak test was performed. Following pelvic wash-out, a drainage tube was placed posteriorly to the anastomosis through the bottom-left working pore. For ultralow anastomoses, or for patients who received neoadjuvant therapy, a protecting LI was performed through the extended bottom-right working pore (Figure 8).

Primary Evaluation Variables

We analyzed surgical safety, pathology outcomes, postoperative recovery, and early follow-up data for each patient

FIGURE 5. The specimen was removed and inspected. For this case, the distance from the lower edge of the lesion to the resection line was approximately 1 cm (ensuring an adequate distal margin). The margin was confirmed by pathologic examination.

Copyright © 2015 Wolters Kluwer Health, Inc. All rights reserved.

FIGURE 6. Preparation of the distal rectum. Two 2–0 Prolene sutures were placed on both extremities of the resection line, and the rectal stump including both ''dog ears'' of the resection line was completely loaded into the cartridge of the KOL® stapler by pulling the tails of the stitches through the windows on the instrument.

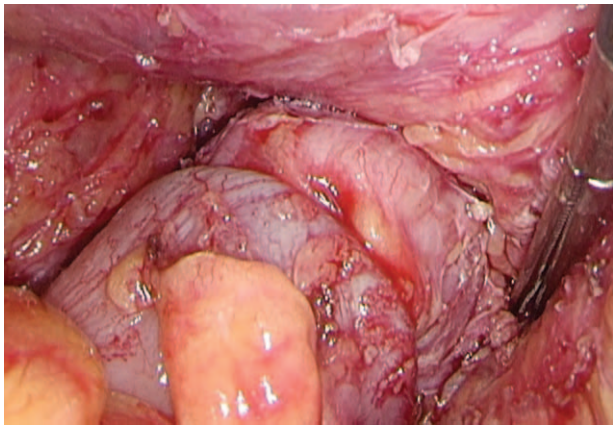

FIGURE 7. A nondog ear anastomosis was performed under laparoscopic guidance. Using the KOL® stapler set, an end-to-end colorectal anastomosis was completed for patients with ultralow rectal cancer using this combined lap laparoscopic low anterior resection and eversion technique.

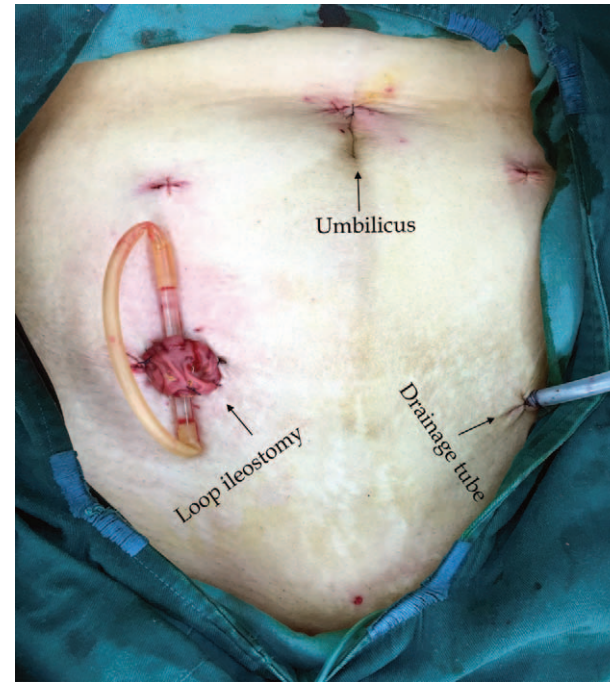

FIGURE 8. The abdominal appearance after surgery. The extended bottom-right working pore can be used to extract the proximal colon and perform a protecting loop ileostomy when required. The extended bottom-left working pore can be used to place a pelvic drainage tube.

(see below for details). Follow-up evaluations consisted of periodic physical and endoscopic examinations. The date of the last follow-up visit was May 15, 2015.

RESULTS

Patient Characteristics

In approximately 1-year period, a total of 11 patients, 6 (54.5%) men and 5 women, underwent surgery. The median age of the patients was 62 (41–76) years. The median body mass index (BMI) was 22.89 (18.03–29.3) kg/m^2. The patient characteristics are summarized in Table 1.

Operative Outcomes

The actual location of the lesions was determined for each after eversion. The median distance from the lower edge of the lesion to the dentate line was 4.5 (3.5–6) cm. The mean operative time was 191 (129–292) minutes. The mean blood loss was 110 (30–300) mL. No patient required a blood transfusion. None had a positive result of air leak test after anastomosis. Eight of the 11 (77.2%) patients received a protecting LI. Other operative outcomes are presented in Table 2.

Pathologic Assessments

The median distance of distal margin was 1.5 (0.5–2.5) cm above from the dentate line. All of the resection margins, including the proximal, distal, and circumferential resection margins, were negative. All margins were negative for lymphovascular invasion, perineural invasion, and extranodal

Copyright © 2015 Wolters Kluwer Health, Inc. All rights reserved.

TABLE 1. Patients' Characteristics

ID	Sex	Age (years)	BMI (kg/m^2)	ASA Grade	Location (cm)*	cTNM (T/N by MRI)	Neoadjuvant CRT	ycTNM (T/N by MRI)
1	Male	59	20.06	1	4	cT2N0M0, I	No	–
2	Male	41	18.03	2	5	cT3N1bM0, IIIb	Yes	ycT2N0M0, I
3	Male	69	20.52	1	5	cT2N1aM0, IIIa	Refused	–
4	Male	75	22.15	2	5	cT2N1aM0, IIIa	Yes	ycCR
5	Female	76	22.89	2	5	cT2N0M0, I	No	–
6	Male	52	23.05	2	4	cTisN0M0, 0	No	–
7	Female	57	29.3	2	7	cT2N1aM0, IIIa	Yes	ycT2N0M0, I
8	Male	62	27.68	1	7	cT2N0M0, I	No	–
9	Female	62	23.42	2	3	cT2N0M0, I	No	–
10	Female	71	22.19	3	3	cT2N0M0, I	No	–
11	Female	66	24.98	2	4	cT3N1bM0, IIIb	Yes	ycT2N0M0, I

ASA = the American Society of Anesthesiologists; BMI = body mass index; CRT = chemoradiation therapy; MRI = magnetic resonance imaging.
* The distance from lower edge of the lesion to the dentate line was initially determined by rigid proctoscopy.

tumor deposits. The pathologic assessments, including pre- and postoperative TNM staging, are presented in Table 3.

Postoperative Complications and Early Follow-Up Data

The patients completed a median length of follow-up of 4.9 (0.2–11.2) months. Most patients had uneventful postoperative recoveries. No patient experienced anastomotic leaks or rupture after surgery. One patient (No. 2) experienced anastomotic bleeding on postoperative day 2, and he was treated with endoscopic hemostatic therapy. His LI had not been reversed till now owing to the moderate to severe radiation proctitis. Another patient (No. 7) developed mild anastomotic stricture 2 months following surgery and underwent endoscopic follow-up without any intervention. Most patients demonstrated an acceptable stool frequency following LI closure. Table 4 showed the postoperative recovery and early follow-up data. A representative endoscopic finding of the anastomosis 3 months after surgery (before LI closure) is presented for one patient (No. 6) (Figure 9).

DISCUSSION

Laparoscopic low and ultralow anterior resection coupled with the eversion technique has been used for decades and increases the possibility of sphincter preservation for patients with distal rectal cancer. Here, we report a combination of these techniques using a well-designed commercial stapling set. Our preliminary data confirmed the surgical safety and technical feasibility of achieving both an oncologically safe distal margin, and a sound end-to-end anastomosis without dog ear formation for patients with distal rectal cancer.

Owing to the potential risk of microscopic involvement of the rectal wall below the tumor, the distance from the lower edge of the rectal lesion to the anal verge has been considered to be the key factor in the decision-making process for sphincter-saving resection. According to general consensus, distal retrograde lymphatic spread is rare and a 1-cm distal margin is acceptable for small lesions without unfavorable histopathologic features.[29,37–40] The transanal eversion and prolapse techniques can facilitate the identification of the resection line to ensure an adequate distal margin for ultralow rectal neoplasms.

TABLE 2. The Patient's Operative Outcomes

ID	Actual Location of the Lesion (cm)*	Protecting Loop Ileostomy	Operation Time (Minutes)	Loss of Blood (mL)	Length of Hospital Stay (Days)	Pelvic Draining (Days)
1	4	Yes	197	120	9	7
2	3.5	Yes	292	300	13	7
3	5	No	182	50	10	7
4	4.5	Yes	205	80	9	7
5	4.5	No	129	50	6	6
6	4	Yes	170	80	5	5
7	5	Yes	209	150	8	7
8	6	No	142	100	11	7
9	3.5	Yes	215	150	10	7
10	3.5	Yes	152	30	9	7
11	4.5	Yes	210	100	7	6

* This was determined by measuring the distance from the lesion's lower edge to the dentate line after eversion.

Copyright © 2015 Wolters Kluwer Health, Inc. All rights reserved.

TABLE 3. Pathologic Assessments for Patients

ID	cTNM/ycTNM (when surgery)	Distant Margin Distance (cm)*	Differentiation Grade	Lymph Node Status	pTNM/ypTNM	TRG Score***
1	cT2N0M0, I	1.5	G2	0/12-	pT2N0M0, I	/
2	ycT2N0M0, I	1	G3	0/6	ypCR	1
3	cT2N1aM0, IIIa	2.5	G2	1/12	pT2N1aM0, IIIa	/
4	ycCR	1	G2	0/12	ypT2N0M0, I	2
5	cT2N0M0, I	1.5	G1	0/12	pT1N0M0, I	/
6**	cTisN0M0, 0	1.5	NA	0/14	pT0N0M0, 0	/
7	ycT2N0M0, I	1	G4 (mucinous)	0/5	ypT3N0M0, IIa	3
8	cT2N0M0, I	1.5	G2	0/14	pT3N0M0, IIa	/
9	cT2N0M0, I	1.2	G2	0/13	pT2N0M0, I	/
10	cT2N0M0, I	1.5	G2	2/12	pT2N1bM0, IIIa	/
11	ycT2N0M0, I	2	G2	0/6	ypT3N0M0, IIa	2

LN = lynph node; NA = not available; TRG = tumor regression grade; ycCR = clinical complete response after neoadjuvant therapy; ypCR = pathologic complete response after neo-adjuvant therapy.
* This was accessed pathologically by measuring the distance from lower edge of the lesion to the distal resection margin. For Case 6, the lesion was displayed as scar area. All patients have been reviewed to have negative resection margins, including proximal, distal, and circumferential resection margins.
** This patient himself insisted on receiving a radical surgery for the unclear marginal status after the initial endoscopic mucosal resection (EMR) for the rectal neoplasm. Initial pathologic diagnosis was intraepithelial neoplasm, high grade. Pathologic examination for him revealed no primary neoplasm could be detected.
*** Mandard TRG Score system was used for patients with neoadjuvant therapy. TRG1: no viable cancer cells, complete response; TRG2: single cells or small groups of cancer cells; TRG3: residual cancer outgrown by fibrosis; TGR4: significant fibrosis outgrown by cancer; TRG5: no fibrosis with extensive residual cancer. (Refrence: Int J Surg Oncol. 2013; 2013: 572149).

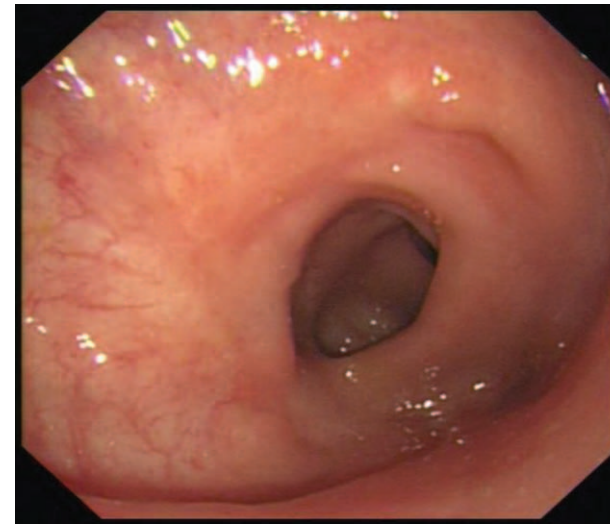

FIGURE 9. Representative endoscopic finding of the anastomosis after surgery. This was taken from a patient (No. 6) 3 months after surgery. A routine endoscopic examination was performed before the closure of his loop ileostomy. It revealed that the anastomotic wall appeared to be smooth, slightly stenosis but unobstructed.

At the lateral intersecting margins in the DST anastomosis, staples formed by linear cutter may be cut by circular cutter. This has been verified on swine models under radiography by Roumen et al.[35] The authors also tested the burst pressures (BP) in 2 types of anastomoses (Group A: n = 35, circular anastomoses without dog ear formation; Group B: n = 32, double-stapled anastomoses with bilateral dog ears). Group A demonstrated significantly higher burst pressures than Group B (median, 90 versus 60 mmHg; $P < 0.001$). Remarkably, in Group B, 13 (40.6%) patients experienced their first disruption at the corner of a dog ear. In a subgroup of patients with low-lying rectal cancer, Zong et al[41] also observed a significantly higher leakage rate when using DST compared with the improved Bacon procedure.

During open surgery, the dog ears formed by DST anastomoses can be safely sutured under direct vision, although it is technically impossible for patients with a narrow pelvis or an ultralow anastomosis.[25] This repair may decrease the risk of developing an anastomotic event. It, however, is not feasible to perform a regular repair in laparoscopic surgery. During Lap LAR the multiple firings on the resection line are technically inevitable.[42] This may cause tissue ischemia and contribute to anastomotic leakage.[35,43–45]

An end-to-end (nondog ears) anastomosis may decrease this risk caused by traditional DST anastomosis. Method that could avoid dog ear formation had been tested in a porcine model by Kvasha et al using a circular stapler (Autosuture, EEA, Covidien, CT). The authors demonstrated the feasibility of endolumenal excision of a substantial length of bowel and transanal natural orifice specimen extraction without rectal stump opening. A mass associated with the resected bowel, however, could hinder the completion of eversion procedure on human subjects.[46,47] The double housing volume of KOL® stapler design ensures the complete resection of the 2 suture lines (of the proximal colon and the rectal stump). Therefore it eliminates the potential ''dog ears'' following full-thickness end-to-end anastomosis (Figure 6).

Copyright © 2015 Wolters Kluwer Health, Inc. All rights reserved.

TABLE 4. Postoperative Complication and Other Follow-Up Data

ID	Major Postoperative Complication	Follow-Up (Months)	Stool Frequency (Times/Day)**	LI Reversal
1	No	11.2	2–4	2 months after surgery
2*	Acute anastomotic bleeding at postoperative day 2	7.2	NA	Not reversed owing to radiation proctitis with intermittent hemorrhage
3	No	6.6	4–6	No LI
4	No	5.8	1–3	2.5 months after surgery
5	No	5.0	6-10	No LI
6	No	4.9	2–3	3 months after surgery
7	Mild anastomotic stricture	4.4	5–8	4 months after surgery
8	No	3.0	2–4	No LI
9	No	2.6	NA	Not yet
10	No	2.6	4–6	2.5 months after surgery
11	No	0.2	NA	Not yet

LI = loop ileostomy.
* Colonoscopy examination at 5 months after surgery revealed that his anastomotic wall appeared to be slightly thickened but without obvious stenosis; featured as radiation proctitis and with mild hemorrhage.
** These data may be not available (NA) for patients had an unreversed loop ileostomy.

Meng et al[48] reported a successful synchronous transanal endoscopic microsurgery-TME procedure on patients with narrow pelvic opening and bulky rectal tumors by using the KOL® staple set. The intralumenal purse-string installation of the rectal stump via a circular anal dilator seemed to be time consuming. Recently, Crafa et al[49] also presented their experience in avoiding dog ear formation in low colorectal anastomoses using the same staple set. After resection of the rectum distally (not proximally) to the lesion, transanal placement of 4 sutures on the rectal stump was performed intracorporeally. Then the rectum was everted and the remaining steps were similar to ours. The procedure they described, however, seemed to be technically challenging in laparoscopy setting and not applicable to patients with an ultralow rectal tumor.

For patients with mid to distal rectal cancer with deep tumor infiltration (T3–4) or positive lymph node involvement (N1–2), radiation or chemoradiation therapy before surgery is recommended. The neoadjuvant therapy can reduce the locoregional recurrence[10,50] and enhance the possibility of sphincter preservation.[51,52] In the current study, 5 patients were cT3 or LN-positive (N1a or 1b). Four of them were treated with neoadjuvant therapy, and most patients underwent this combined procedure successfully. Moreover, the eversion procedure helps to detect the reduced lesion more clearly under direct vision for patients after neoadjuvant therapy. This is especially important for those who only has a ''scar-liking'' lesion or clinical complete response after neoadjuvant therapy (ycCR).

In the current report, most patients had a normal BMI value (Table 1). Our preliminary data indicates that this combination technique is a safe procedure. This technique may be applicable for patients with a narrow pelvis, difficult anastomosis location, or even patients requiring a salvage technique following stapling failure. The eversion operation, however, may not be applicable to obese patients with hypertrophic mesorectum or patients with bulky tumors.

One of the disadvantage of the eversion technique and sphincter saving surgery for patients with an ultralow rectal cancer is that it may lead to poor defecation control after surgery. Furthermore, during prolapse procedure, the mucosal epithelium 1 to 2 cm above the dentate line should be retained carefully because many epithelial sensory nerve endings in this area. Importantly, elderly patients or patients with preoperative anal dysfunction should not undergo sphincter preservation.

One of the limitations of this study was the lack of endoscopic ultrasound for T staging. Instead, we used magnetic resonance imaging examinations for both T and N preoperative staging. This staging approach underestimates (4/11) the T stage and overall TNM staging (No. 7, 8, 10, and 11, see Table 3). Guillem et al,[53] however, suggested that although some patients may be overstaged (and thus overtreated), more patients would be understaged and require postoperative chemoradiation therapy. Another limitation was that the current preliminary study was underpowered with only 11 patients and definitive conclusions were not possible. We are establishing a randomized clinical trial to investigate the risk of leaks between anastomoses with and without dog ears, and we look forward to reporting these results in the near future.

In summary, Lap LAR with TME coupled with the synchronous pull-through technique are well-established procedures for patients with low or ultralow rectal neoplasms. We combined these currently available techniques with a commercial stapling set to achieve an oncologically safe distal margin. Our preliminary data also confirmed the technical feasibility of achieving a sound end to end anastomosis without dog ear formation.

REFERENCES

1. Morino M, Risio M, Bach S, et al. Early rectal cancer: the European Association for Endoscopic Surgery (EAES) clinical consensus conference. *Surg Endosc.* 2015:755–773.
2. Nascimbeni R, Burgart LJ, Nivatvongs S, et al. Risk of lymph node metastasis in T1 carcinoma of the colon and rectum. *Dis Colon Rectum.* 2002;45:200–206.
3. Yamamoto S, Watanabe M, Hasegawa H, et al. The risk of lymph node metastasis in T1 colorectal carcinoma. *Hepato-gastroenterology.* 2004;51:998–1000.
4. Smith KJ, Jones PF, Burke DA, et al. Lymphatic vessel distribution in the mucosa and submucosa and potential implications for T1 colorectal tumors. *Dis Colon Rectum.* 2011;54:35–40.

Copyright © 2015 Wolters Kluwer Health, Inc. All rights reserved.

5. Saraste D, Gunnarsson U, Janson M. Predicting lymph node metastases in early rectal cancer. *Eur J Cancer (Oxford, England: 1990).* 2013;49:1104–1108.
6. Heald RJ. Total mesorectal excision is optimal surgery for rectal cancer: a Scandinavian consensus. *Br J Surg.* 1995;82:1297–1299.
7. Ridgway PF, Darzi AW. The role of total mesorectal excision in the management of rectal cancer. *Cancer Control.* 2003;10:205–211.
8. Kapiteijn E, Marijnen CA, Nagtegaal ID, et al. Preoperative radiotherapy combined with total mesorectal excision for resectable rectal cancer. *N Engl J Med.* 2001;345:638–646.
9. Murty M, Enker WE, Martz J. Current status of total mesorectal excision and autonomic nerve preservation in rectal cancer. *Semi Surg Oncol.* 2000;19:321–328.
10. Sauer R, Becker H, Hohenberger W, et al. Preoperative versus postoperative chemoradiotherapy for rectal cancer. *N Engl J Med.* 2004;351:1731–1740.
11. Jacobs M, Verdeja JC, Goldstein HS. Minimally invasive colon resection (laparoscopic colectomy). *Surg Laparosc Endosc.* 1991;1:144–150.
12. Kang SB, Park JW, Jeong SY, et al. Open versus laparoscopic surgery for mid or low rectal cancer after neoadjuvant chemoradiotherapy (COREAN trial): short-term outcomes of an open-label randomised controlled trial. *Lancet Oncol.* 2010;11:637–645.
13. van der Pas MH, Haglind E, Cuesta MA, et al. Laparoscopic versus open surgery for rectal cancer (COLOR II): short-term outcomes of a randomised, phase 3 trial. *Lancet Oncol.* 2013;14:210–218.
14. Arezzo A, Passera R, Scozzari G, et al. Laparoscopy for rectal cancer reduces short-term mortality and morbidity: results of a systematic review and meta-analysis. *Surg Endosc.* 2013;27:1485–1502.
15. Kennedy RH, Francis EA, Wharton R, et al. Multicenter randomized controlled trial of conventional versus laparoscopic surgery for colorectal cancer within an enhanced recovery programme: EnROL. *J Clin Oncol.* 2014;32:1804–1811.
16. Green BL, Marshall HC, Collinson F, et al. Long-term follow-up of the Medical Research Council CLASICC trial of conventional versus laparoscopically assisted resection in colorectal cancer. *Br J Surg.* 2013;100:75–82.
17. Vennix S, Pelzers L, Bouvy N, et al. Laparoscopic versus open total mesorectal excision for rectal cancer. *Cochrane Database Syst Rev.* 2014;4:Cd005200.
18. Bonjer HJ, Deijen CL, Abis GA, et al. A randomized trial of laparoscopic versus open surgery for rectal cancer. *N Engl J Med.* 2015;372:1324–1332.
19. Corman ML. Classic articles in colonic and rectal surgery. A new method of excising the two upper portions of the rectum and the lower segment of the sigmoid flexure of the colon: by H. Widenham Maunsell. *Dis Colon Rectum.* 1981;24:649–654.
20. Bennett RS. The place of pull-through operations in treatment of carcinoma of the rectum. *Dis Colon Rectum.* 1976;19:420–424.
21. Di Betta E, D'Hoore A, Filez L, et al. Sphincter saving rectum resection is the standard procedure for low rectal cancer. *Int J Colorectal Dis.* 2003;18:463–469.
22. Kim H, Choi G-S, Park J, et al. Comparison of intracorporeal single-stapled and double-stapled anastomosis in laparoscopic low anterior resection for rectal cancer: a case-control study. *Int J Colorectal Dis.* 2013;28:149–156.
23. Varma JS, Chan AC, Li MK, et al. Low anterior resection of the rectum using a double stapling technique. *Br J Surg.* 1990;77:888–890.
24. Fu CG, Muto T, Masaki T. Results of the double stapling procedure in colorectal surgery. *Surg Today.* 1997;27:706–709.
25. Sato H, Maeda K, Hanai T, et al. Modified double-stapling technique in low anterior resection for lower rectal carcinoma. *Surg Today.* 2006;36:30–36.
26. Heald RJ. The ''Holy Plane'' of rectal surgery. *J R Soc Med.* 1988;81:503–508.
27. Watanabe M, Teramoto T, Hasegawa H, et al. Laparoscopic ultralow anterior resection combined with per anum intersphincteric rectal dissection for lower rectal cancer. *Dis Colon Rectum.* 2000;43:S94–97.
28. Fukunaga M, Kidokoro A, Iba T, et al. Laparoscopy-assisted low anterior resection with a prolapsing technique for low rectal cancer. *Surg Today.* 2005;35:598–602.
29. Fu CG, Gao XH, Wang H, et al. Treatment for early ultralow rectal cancer: pull-through intersphincteric stapled transection and anastomosis (PISTA) versus low anterior resection. *Tech Coloproctol.* 2013;17:283–291.
30. Schiessel R, Karner-Hanusch J, Herbst F, et al. Intersphincteric resection for low rectal tumours. *Br J Surg.* 1994;81:1376–1378.
31. Ito M, Saito N, Sugito M, et al. Analysis of clinical factors associated with anal function after intersphincteric resection for very low rectal cancer. *Dis Colon Rectum.* 2009;52:64–70.
32. Han JG, Wei GH, Gao ZG, et al. Intersphincteric resection with direct coloanal anastomosis for ultralow rectal cancer: the experience of People's Republic of China. *Dis Colon Rectum.* 2009;52:950–957.
33. Hohenberger W, Merkel S, Matzel K, et al. The influence of abdomino-peranal (intersphincteric) resection of lower third rectal carcinoma on the rates of sphincter preservation and locoregional recurrence. *Colorectal Dis.* 2006;8:23–33.
34. Yamada K, Ogata S, Saiki Y, et al. Long-term results of intersphincteric resection for low rectal cancer. *Dis Colon Rectum.* 2009;52:1065–1071.
35. Roumen RM, Rahusen FT, Wijnen MH, et al. Dog ear formation after double-stapled low anterior resection as a risk factor for anastomotic disruption. *Dis Colon Rectum.* 2000;43:522–525.
36. Watanabe M. Laparoscopic Anterior Resection for Rectal Cancer. In: Milsom JW, Böhm B, Nakajima K, Tonohira Y, eds. *Laparoscopic colorectal surgery.* 2nd ed. New York: Springer; 2006:170–187.
37. Williams NS, Dixon MF, Johnston D. Reappraisal of the 5 centimetre rule of distal excision for carcinoma of the rectum: a study of distal intramural spread and of patients' survival. *Br J Surg.* 1983;70:150–154.
38. Pollett WG, Nicholls RJ. The relationship between the extent of distal clearance and survival and local recurrence rates after curative anterior resection for carcinoma of the rectum. *Ann Surg.* 1983;198:159–163.
39. Rullier E, Laurent C, Bretagnol F, et al. Sphincter-saving resection for all rectal carcinomas: the end of the 2-cm distal rule. *Ann Surg.* 2005;241:465–469.
40. Tjandra JJ, Kilkenny JW, Buie WD, et al. Practice parameters for the management of rectal cancer (revised). *Dis ColonRectum.* 2005;48:411–423.
41. Zong L, Chen P, Kitano S, et al. Clinical experience and analysis of laparoscopic total mesorectal excision combined with improved bacon for the treatment of lower rectal cancer. *Hepato-gastroenterology.* 2011;58:1538–1544.
42. Kuroyanagi H, Oya M, Ueno M, et al. Standardized technique of laparoscopic intracorporeal rectal transection and anastomosis for low anterior resection. *Surgical Endosc.* 2008;22:557–561.
43. Leroy J, Jamali F, Forbes L, et al. Laparoscopic total mesorectal excision (TME) for rectal cancer surgery: long-term outcomes. *Surgical Endosc.* 2004;18:281–289.
44. Ito M, Sugito M, Kobayashi A, et al. Relationship between multiple numbers of stapler firings during rectal division and anastomotic

Copyright © 2015 Wolters Kluwer Health, Inc. All rights reserved.

leakage after laparoscopic rectal resection. *Int J Colorectal Dis.* 2008;23:703–707.

45. Kawada K, Hasegawa S, Hida K, et al. Risk factors for anastomotic leakage after laparoscopic low anterior resection with DST anastomosis. *Surgical Endosc.* 2014;28:2988–2995.
46. Kvasha A, Kvasha V, Hadary A, et al. Endolumenal rectal resection and transanal natural orifice specimen extraction (NOSE) without rectal stump opening: a novel, clean surgical technique in a porcine model. *Surg Innov.* 2013;20:454–458.
47. Kvasha A, Hadary A, Biswas S, et al. Novel totally laparoscopic endolumenal rectal resection with transanal natural orifice specimen extraction (NOSE) without rectal stump opening: a modification of our recently published clean surgical technique in a porcine model. *Surgical Innov.* 2015;22:245–251.
48. Meng W, Lau K. Synchronous laparoscopic low anterior and transanal endoscopic microsurgery total mesorectal resection. *MITAT.* 2014;23:70–73.
49. Crafa F, Megevand J, Romano G, et al. New double-stapled anastomotic technique to avoid crossing staple lines. *Techniques Coloproctol.* 2015;19:319–320.
50. Rahbari NN, Elbers H, Askoxylakis V, et al. Neoadjuvant radiotherapy for rectal cancer: meta-analysis of randomized controlled trials. *Ann Surg Oncol.* 2013;20:4169–4182.
51. Wagman R, Minsky BD, Cohen AM, et al. Sphincter preservation in rectal cancer with preoperative radiation therapy and coloanal anastomosis: long term follow-up. *Int J Radiat Oncol Biol Phys.* 1998;42:51–57.
52. Luna-Perez P, Rodriguez-Ramirez S, Hernandez-Pacheco F, et al. Anal sphincter preservation in locally advanced low rectal adenocarcinoma after preoperative chemoradiation therapy and coloanal anastomosis. *J Surg Oncol.* 2003;82:3–9.
53. Guillem JG, Diaz-Gonzalez JA, Minsky BD, et al. cT3N0 rectal cancer: potential overtreatment with preoperative chemoradiotherapy is warranted. *J Clin Oncol.* 2008;26:368–373.

Copyright © 2015 Wolters Kluwer Health, Inc. All rights reserved.