

Tailored prolapse surgery for the treatment of haemorrhoids and obstructed defecation syndrome with a new dedicated device: TST STARR Plus

Gabriele Naldini, Jacopo Martellucci, Roberto Rea, Stefano Lucchini, Michele Schiano di Visconte, Angelo Caviglia, Claudia Menconi, et al.

International Journal of Colorectal Disease

Clinical and Molecular Gastroenterology and Surgery

ISSN 0179-1958

Int J Colorectal Dis

DOI 10.1007/s00384-014-1845-7



Your article is protected by copyright and all rights are held exclusively by Springer-Verlag Berlin Heidelberg. This e-offprint is for personal use only and shall not be self-archived in electronic repositories. If you wish to self-archive your article, please use the accepted manuscript version for posting on your own website. You may further deposit the accepted manuscript version in any repository, provided it is only made publicly available 12 months after official publication or later and provided acknowledgement is given to the original source of publication and a link is inserted to the published article on Springer's website. The link must be accompanied by the following text: "The final publication is available at link.springer.com".

Tailored prolapse surgery for the treatment of haemorrhoids and obstructed defecation syndrome with a new dedicated device: TST STARR Plus

Gabriele Naldini · Jacopo Martellucci · Roberto Rea · Stefano Lucchini · Michele Schiano di Visconte · Angelo Caviglia · Claudia Menconi · Donglin Ren · Ping He · Domenico Mascagni

Accepted: 11 February 2014

© Springer-Verlag Berlin Heidelberg 2014

Abstract

Objective The aim of the study was to assess the safety, efficacy and feasibility of stapled transanal procedures performed by a new dedicated device, TST STARR Plus, for tailored transanal stapled surgery.

Methods All the consecutive patients admitted to eight referral centres affected by prolapses with III-IV degrees haemorrhoids or obstructed defecation syndrome (ODS) with rectocele and/or rectal intussusception that underwent stapled transanal resection with TST STARR plus were included in the present study. Haemostatic stitches for bleeding of the suture line, specimen

volume, operative time, hospital stay and perioperative complications were recorded.

Results From 1 November 2012 to 31 March 2013, 160 consecutive patients (96 females) were enrolled in the study. In 94 patients, the prolapse was over the half of the circular anal dilator (CAD). The mean duration of the procedure was 25 min. The mean resected volume of the specimen was 13.3 cm³, the mean hospital stay was 2.2 days. In 88 patients (55 %), additional stitches on the suture line were needed (mean 2.1). Suture line dehiscence was reported in four cases, with intraoperative

What does this paper add to the literature? This is the first study analyzing this new device for prolapse surgery. In this prospective, multicentric study, the safety and the efficacy of the new stapler were evaluated, with convincing results. An improvement in the stapler closure system, the open case with mega windows and an improved staple line were considered essential for a reduction of recurrences and complications.

G. Naldini · C. Menconi
Proctological and Perineal Surgery, University Hospital of Pisa, Pisa, Italy

J. Martellucci (✉)
General, Emergency and Minimally Invasive Surgery I, Careggi University Hospital, Florence, Italy
e-mail: jamjac64@hotmail.com

R. Rea
General Surgery Department, Clinica Mediterranea, Naples, Italy

S. Lucchini
General Surgery Department, Castel S. Giovanni Hospital, Piacenza, Italy

M. Schiano di Visconte
General Surgery Department, S. Maria dei Battuti Hospital, Conegliano, Treviso, Italy

A. Caviglia
Colonproctology Surgery Unit, San Camillo-Forlanini Hospital, Rome, Italy

D. Ren
Proctological Surgery, Gastric and Intestine Hospital, Sun Yi San University, Guangzhou Hospital, Guangzhou, China

P. He
Proctological Surgery, Colorectal Hospital, Chengdu Traditional Chinese Medicine University, Chengdu, China

D. Mascagni
Surgical Science Department, La Sapienza University, Rome, Italy

reinforcement. Bleeding was reported in seven patients (5 %). Urgency after 30 days was reported in one patient. No major complication occurred.

Conclusions The new device seems to be safe and effective for a tailored approach to anorectal prolapse due to haemorrhoids or obstructed defecation.

Keywords Stapled surgery · Haemorrhoids · Obstructed defecation · STARR · Stapled hemorrhoidectomy · Stapled hemorrhoidopexy · Prolapse

Introduction

In the last years, stapled transanal resections for haemorrhoids and obstructed defecation syndrome (ODS) have been adopted worldwide with convincing short-term results. The mean weaknesses of these procedures were related to recurrence rate and some major complications that can occur. Considering that a larger resection could help to prevent or delay recurrence and that a better technology could help to reduce some important complications, such as perioperative bleeding, the need of a revision and an evolution of the devices and the procedures seem to be essential.

The aim of the study was to assess the safety, the efficacy and the feasibility of stapled transanal procedures performed by a new dedicated device for tailored transanal stapled surgery.

Materials and methods

All the consecutive patients admitted from January to March 2013 in eight referral centres (six in Italy and two in China) affected by III–IV-degree hemorrhoidal prolapses and ODS with rectocele and/or rectal intussusception that underwent stapled transanal resection with the TST Stapled Transanal Rectal Resection (STARR) Plus were included in the present study. A minimum of seven procedures per centre were required (Fig. 1).

Previous stapled or perineal surgery and the need of associated procedures for proctologic comorbidities were considered as exclusion criteria from the study.

Patients with non-relaxing puborectalis muscle, with genital prolapse or cystocele requiring associated transvaginal operations, faecal incontinence (Wexner score >3), mental disorders or general contraindications to surgery were excluded.

Preoperatively, a clinical evaluation, proctoscopy and transanal ultrasound were performed in every patient, associated with cinedefecography and anorectal manometry in patients affected by ODS.

Cleveland Clinic Score for Incontinence [1] was performed before and 30 days after surgery. Cleveland Clinic Score for

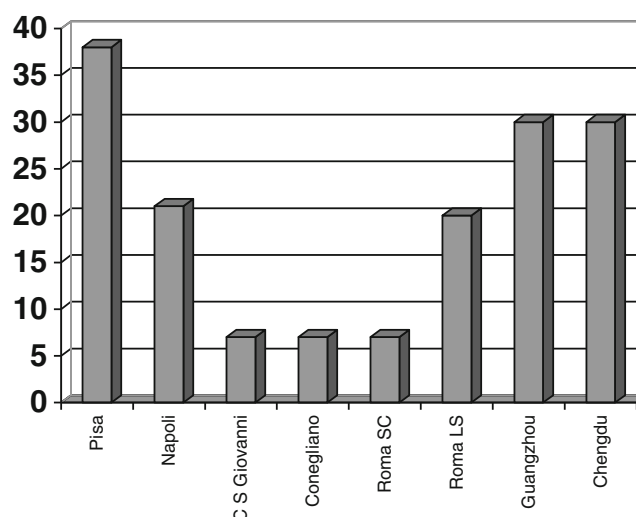


Fig. 1 Number of procedures/centre (Pisa 39, Napoli 21, Castel S. Giovanni 7, Conegliano 7, Roma San Camillo 7, Roma La Sapienza 20, Guangzhou 30, Chengdu 30)

Constipation [2] was also performed in every patient affected by ODS before and 30 days after surgery.

Pain was measured with a Visual Analogue Scale (VAS, 1–10) before the operation, after 24 h, and at every follow-up evaluation. Patient satisfaction was measured 30 days after surgery with a four-item scale, asking to define the result of the procedure as excellent, good, sufficient or poor.

Follow-up was performed between 7 and 15 days and after 30 days and recorded in every centre using an agreed form.

Haemostatic perianastomotic stitches for bleeding of the suture line, operative time, hospital stay and perioperative complications (occurred in the 30 postoperative days) were recorded.

Device features The TST STARR Plus stapler (Touchstone International Medical Science Co., Ltd, Suzhou, China) has a housing length of 6 cm, a housing volume of more than 35 cm³, an external diameter of 36 mm, a blade diameter of 28 mm, 34 staplers with an open height of 4.2 mm with a closure range 0.75–1.8 mm.

For a better view of the operatory field and the tissue to resect, The Mega-WindowsTM and Barrier-FreeTM open case offers the surgeon a better view of the operating field and of the resectable tissue volume (Fig. 2). Four new patents have been used to minimize the possibility of a wrong staple closure: the metal built-in adjustment, the anti-retrieving lock, the permanent balance technology and the permanent parallel control.

All the procedures were performed by surgeons with experience in stapled transanal surgery according to the following standardized technique (Fig. 3).

Surgical procedures were performed in sub-arachnoid anaesthesia with the patient in gynaecologic/lytotoxic position.

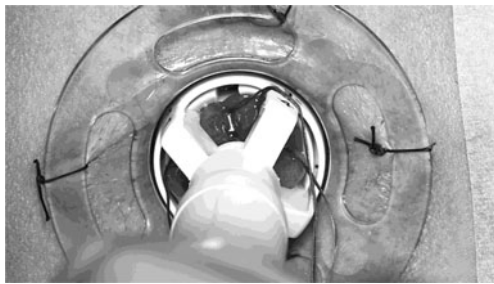


Fig. 2 Complete visualization of the prolapse

After the circular anal dilator (CAD) introduction, using a piece of gauze held by a pincer, the prolapsed rectal wall was drawn into the CAD to identify the prolapsing tissue to be removed. If the prolapse was less than half of the CAD the procedure was performed with a purse string suture. If the prolapse exceeds the half of the CAD, the parachute technique was used, with 6 short running sutures at 1,3,5,7,9,11 o'clock. The parachute technique allowed to attract into the case a larger amount of tissue and to better manage asymmetrical prolapses.

The suture line was considered correctly realized if it was finally located at the apex of the hemorrhoidal tissue.

Before firing the stapler, the posterior vaginal wall was carefully checked with fingers and a vaginal valve to prevent entrapment.

The volume and length of resected specimen was measured in every patient (Fig. 4). The volume (whether regularly or irregularly shaped) was determined by fluid displacement by immersing the resected tissue in a measuring cup filled by water. Then the increase of the liquid level was registered (in cubic centimetres).

Fig. 3 Surgical procedure: (a) After the CAD introduction, the prolapsed rectal wall was drawn into the CAD to identify the prolapsing tissue to be removed; (b) the tissue was attracted into the case; (c) the staple firing was performed under direct vision; (d) the resected specimen was controlled.

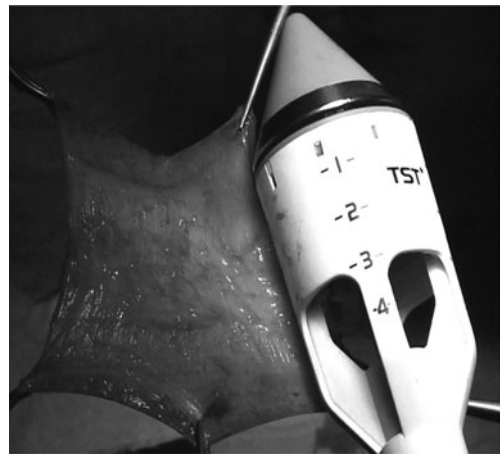
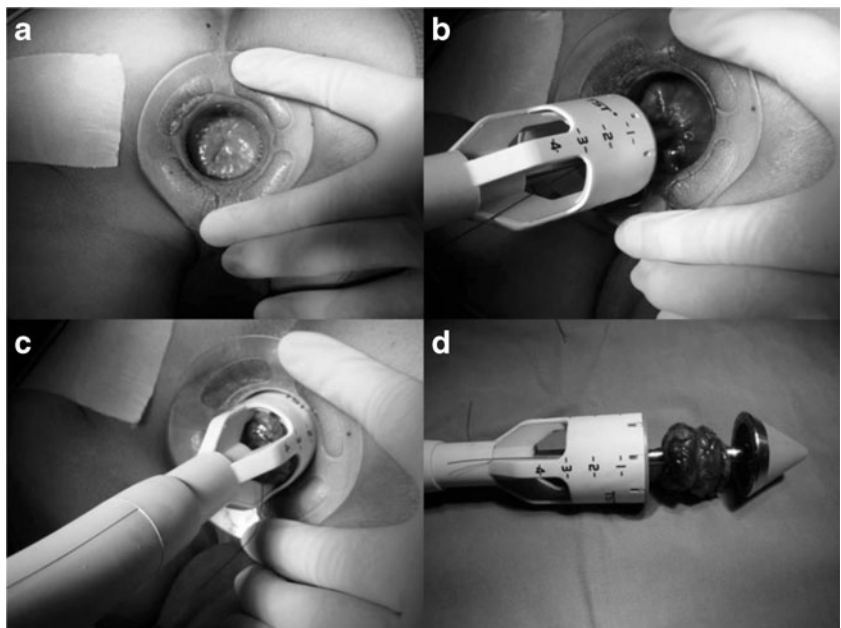


Fig. 4 Resected specimen evaluation

The postoperative analgesic protocol provided opioids in the operative day, NSAID-paracetamol in the following 3 days administered every 6–8 h and from the 4th postoperative day, NSAID-paracetamol just in case of pain.

Data were prospectively recorded into a dedicated database; statistical analysis was performed using the Statistical Package for the Social Sciences (SPSS 13, Chicago, IL, USA). The difference between pre and post-treatment data was analyzed by a *t* test. The difference was considered statistically significant for *p* values <0.05.

Results

From 1 November 2012 to 31 March 2013, 160 consecutive patients (106 females) were enrolled in the study. The

indication for surgery was haemorrhoids in 84 patients (34 females) and ODS due to rectocele and/or rectal intussusceptions in 76 patients (72 females). In 101 patients (71 with ODS), the prolapse occupied more than half of the CAD.

The main symptoms of patients with haemorrhoids were prolapse (89 %) and bleeding (61 %).

The main reported symptoms of patients with ODS were frequent unsuccessful attempts to defecate (92 %), increased time or straining to defecate (89 %), incomplete defecation (74 %), needs of laxatives/enemas (72 %), low frequency of bowel movements or absence of stimulus to defecation (44 %), pain (13 %) and bleeding (9 %).

Only 26 patients had previously undergone gynaecologic surgery (21 hysterectomy, 4 caesarean, 1 TVT). The average duration of procedure was 25 min (range 13–60 min) with a median hospital stay of 2.2 days (range 1–7 days).

The mean resected volume was 13.3 cm³ (range 8–19 cm³) with a mean high of surgical specimen of 5.18 cm (range 2.5–8 cm).

In the patients with more-than-half-of-the-CAD prolapsed tissue, the mean high of surgical specimen was 6.23 cm (range 3.5–8 cm).

The total mean preoperative VAS value was 1.8, with values of 4, 2.1, 1.8 and 0.5 at 6 h, 24 h, 15 days and 30 days, respectively (Fig. 5).

In patients affected by haemorrhoids, the mean preoperative VAS value was 2, with values of 3.9, 1.6, 2 and 0.3 at 6 h, 24 h, 15 days and 30 days, respectively.

In patients affected by ODS, the mean preoperative VAS value was 1.5, with values of 4.2, 2.7, 1.5 and 0.8 at 6 h, 24 h, 15 days and 30 days, respectively.

Thirty-four patients (22.6 %) required additional analgesics during the hospital stay. At 30 days after surgery, only 2 (1.2 %) patients still need occasional analgesic drugs.

The Cleveland Clinic Constipation Score performed in patients affected by ODS decreased from 13.3 (±2.3) preoperatively to 7.16 (±3.1) postoperatively ($p < 0.001$).

The Cleveland Clinic Incontinence Score performed in every patient changed from 0.54 to 0.86 postoperatively, with no statistically significant difference.

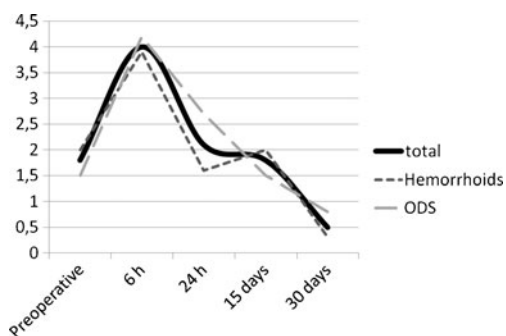


Fig. 5 Pain scale

Patient satisfaction grade in case of haemorrhoids was excellent (51 %), good (38 %), sufficient (9 %) and poor (2 %) (Fig. 6). Patient satisfaction grade in ODS was excellent (42 %), good (32 %), sufficient (23 %) and poor (3 %).

Considering perioperative findings, in 10 patients (6 %), the surgeons reported some difficulties to introduce the CAD, but in no case there was the impossibility to introduce it or any other limitation to the procedure.

In 88 patients (55 %), the surgeons reported the need of additional stitches on the suture line, with a mean number of 2.1 stitches per patient.

A mild perianal hematoma/edema was evidenced in seven patients (4.6 %), but did not require any treatment. In four patients (2.5 %), there was an incomplete suture line, probably due to a wrong traction of the prolapse during the closure of the stapler that required an intraoperative correction with no further consequences.

Considering the postoperative complications (Table 1), variable forms of bleeding were reported in seven patients (4 %), with the need of surgical revision in two patients (the bleeding occurred in the 3rd and 12th postoperative day). The bleeding requiring surgical evaluation occurred in one patient with haemorrhoids (less than half of the CAD) and in one with ODS (more than half of the CAD).

Postoperative urinary retention or delayed spontaneous first micturition was reported in six patients (3.7 %).

Rigid suture with tenesmus was reported in one patient, treated with rectal mesalazin.

Urgency was reported in 14 patients (8.7 %) at 15 days and only in one patient (0.5 %) at 30 days. No other continence disturbance was reported. No major complication occurred.

Discussion

After about 15 years since the first mucoprolapsectomy described by Longo [3], and more than 500 published papers describing indications, results, complications and functional

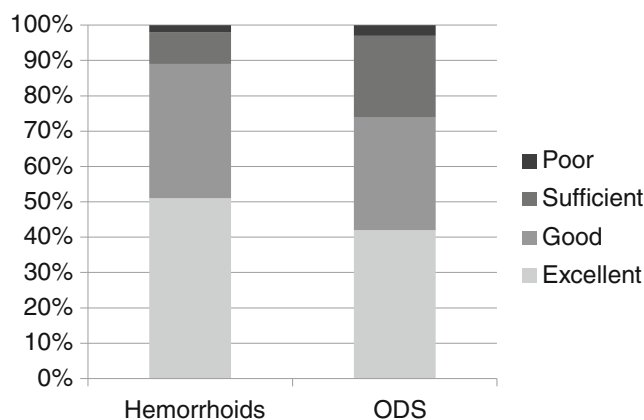


Fig. 6 Satisfaction grade

Table 1 Complications

	Haemorrhoids	ODS	Total	<i>p</i>
Perioperative				
Difficulty introducing CAD	6 (7 %)	4 (5 %)	10 (6 %)	0.6
Incomplete suture line	1 (1 %)	3 (4 %)	4 (2.5 %)	0.2
Additional stitches	41 (48 %)	47 (61 %)	88 (55 %)	0.09
Postoperative				
Bleeding	4 (4 %)	3 (4 %)	7 (4 %)	0.8
Urgency 15 days	6 (7 %)	8 (10 %)	14 (8.7 %)	0.4
Urgency 30 days	0	1 (1 %)	1 (0.5 %)	0.2

outcomes, some problems still remain unsolved and an intense debate is still ongoing.

The effectiveness of stapled resection (hemorrhoidal or rectal) was reported consistently over time [4–16] but the high recurrence rate (especially for hemorrhoidopexy) and some serious complications described [17] have helped to maintain a certain skepticism about these techniques.

The first problem is how to reduce the recurrence rate. The idea that a larger resection means a better result with a lower recurrence rate still has to be demonstrated with long-term results.

The studies that tried to compare a resection performed with double stapled STARR vs a curved stapled STARR (Transtar with Contour CCS30) confirmed that a larger resection is possible with curved stapler, but without commensurate qualitative outcome improvement [18]. However, some studies demonstrate that it is possible to reduce the recurrence rate of stapled hemorrhoidopexy performing a STARR instead of a simple prolapsectomy [19–22]. For these reasons, the possibility of evaluating the amount of the prolapse intraoperatively with a disposable CAD before starting the procedure, together with the possibility to decide the optimal amount of the resection (from 2 to 8 cm) and perform it with a single device with no need to change neither instrumentation nor the procedure (PPH, STARR, Transtar) seems to be essential for a real tailored resection to minimize recurrences. Moreover, the opportunity to check and adjust under direct vision the amount of the prolapse inserted into the device could increase the safety and efficacy of the procedure.

In the present paper, haemorrhoids and ODS were considered together following the consideration that some amount of prolapse was the physiopathological basis of both the diseases. This is also confirmed by the high number of patients treated for haemorrhoids with a primary symptom of prolapse.

From this point of view, performing a tailored surgery allows the treatment of the prolapse (with a single device) regardless of the underlying disease.

Moreover, it is well known that the use of a single stapler for haemorrhoids rarely allows a simple mucosal resection

[23] and that the absence of muscle tissue in the resected specimen could be considered as an independent predictive factor of postoperative persistence of prolapse [24].

As already mentioned, a double stapler procedure (STARR) was successfully described as an effective treatment for large hemorrhoidal prolapses, confirming that the aim of the staple transanal surgery was to treat the prolapsing tissue, not the haemorrhoids (anatomical component) or the obstructed defecation syndrome (functional condition with anatomical alterations).

The second problem is how to reduce or avoid major complications. Some life-threatening complications such as rectal perforation, sepsis, severe extrarectal bleeding and large hematomas, and other major complications among which rectovaginal fistula, chronic pelvic pain and faecal incontinence have been reported [17, 25].

The risk of serious complications after surgery for benign disorders including haemorrhoids or ODS is considered unacceptable by many surgeons, and this is strongly limiting the trust in this type of procedures despite the good results.

One of the main problems concerns how to avoid complications with better technology. Excluding the surgeons' technical errors (probably a significant number in the first period of the transanal stapler surgery experience) and the stapler failure, it is necessary to distinguish between complications related to the use of a stapler, in which a better technology could be determinant, and complications related to the transanal resection procedure, independent of stapler use.

Between 14 November 1994 and 1 July 2001, the FDA received 112 surgical stapler adverse event death reports. The death reports involved staplers that did not fire or staples that did not form properly. There are also reports of suture line separation from staples that did not form or fell off. Over the past 5 years, there have been 8,000 to 9,000 adverse event reports per year related to surgical staplers. Ninety-percent were malfunctions, 9 % injuries and less than 1 % deaths. The most frequently reported device problems were: staples did not form, staplers misfired or failed to fire and separated suture lines. The most frequently reported patient problems were anastomotic failure, prolonged surgery, bleeding, and sepsis [26]. Even if these data are referred to all the stapler surgery (gastrointestinal, gynecologic, thoracic, etc) it is clear how an evolution of the technology could help to prevent some complications.

A thorough analysis of how tissue thickness, compression and staple size and shape (a true B-shape staple) can affect staple line formation is also important to help to prevent complications.

The main complication in which an improvement of the devices could be important is bleeding. The correct use of a device, the number of staples and staple lines, a variable closure range of the staple, with the possibility to adapt to it

according to the tissue are key points to avoid some serious complications related to bleeding (active extrarectal bleeding, retroperitoneal hematomas, etc).

The influence of the stapler device on bleeding was previously reported [27–29], and in our data, only 55 % of the patients required additional stitches for hemostasis, with a mean number of 2.1 stitches, and surgical revision for bleeding was necessary only in two patients, with no major hemorrhagic complications.

Another major complication that could probably be prevented with a conscientious use of an improved device could be related to rectal perforation, anastomosis failure or some septic complications.

Currently, resection is performed 'blind' after trans-anal insertion of the stapler with limitations in the amount of rectal wall that can be resected.

These technical limitations may explain some of the difficulties and complications experienced with the Stapler transanal resection techniques. Even if the curved stapler (Transtar) allows a larger resection, Contour Transtar stapling patients that present with an important rectal prolapse may need additional suturing of the rectal anastomosis, probably due to the thickness of the rectal wall, with a higher risk of staple line failure [30].

Some of these major complications could be avoided by using a surgical device that allows the complete and continuous control of the procedure under direct vision (no blind surgery), by regulating the height of the staples according to the amount of tissue to be resected and to the rectal wall thickness and by a correct regulation of the stapler closure to avoid an incomplete anastomosis.

In our series, an incomplete suture line was reported in four patients (2.5 %), probably due to a wrong traction of the prolapse during the closure of the stapler, which required an intraoperative correction with no further consequences. Unfortunately, even if continence complications (urgency) were reported in 8.7 % of the patients, and just in one patient after 30 days, with no faecal incontinence occurrence, we do not believe that continence alterations could be considered as complications that may be affected by the surgical device used. Further studies are needed to confirm this data.

Moreover, even if favourable results on pain were described in our series, the direct correlation between pain and kind of stapler used is difficult to define.

Pain after stapler procedures was often related to agraphes retention or low staple line, even if a full thickness resection could be related to changes in rectal mobility [23]. Moreover, pain has also been attributed to persistent hemorrhoidal disease, sphincter spasm, rectal spasm or high anal resting pressures, suture dehiscence, anal fissure and anorectal sepsis [25]. Considering that pain after stapler surgery is mostly reported as post-defecatory and that the removal of staples from the puborectalis muscle have been described, it is possible that

after deeper stapled resections the rectum is fixed to the surrounding muscular structures, thus reducing its mobility during defecation and causing traction on the surrounding structures under strain [31].

In the present study, a single device was used for the treatment of anorectal prolapses with haemorrhoids or ODS, with the belief that making the operation easier could reduce the possibility of technical mistakes.

The possibility to regulate the amount of tissue to resect and to perform the resection under direct vision due to the open case could represent a possible way towards a safer and more reliable operation.

Conclusions

From this preliminary data, the new proposed device seems to be safe and effective for a tailored approach to haemorrhoids or obstructed defecation due to anorectal prolapse.

Performing a regulated resection under direct view with a single device could be essential for the reduction of the complications and the recurrences and for the evolution of the stapled transanal rectal resections.

Further studies are required to confirm these initial positive results.

Competing interests The authors have no potential conflict of interests to be disclosed.

References

- Jorge JM, Wexner SD (1993) Etiology and management of fecal incontinence. *Dis Colon Rectum* 36:77–97
- Agachan F, Chen T, Pfeifer J, Reissman P, Wexner SD (1996) A constipation scoring system to simplify evaluation and management of constipated patients. *Dis Colon Rectum* 39:681–685
- Longo A (1998 June 3–6) Treatment of hemorrhoids disease by reduction of mucosa and hemorrhoidal prolapse with a circular suturing device: a new procedure. In: *Proceedings of the 6th World Congress of Endoscopic Surgery*. Rome
- Renzi A, Brillantino A, Di Sarno G, D'Aniello F, Giordano A, Stefanuto A, Aguzzi D, Daffinà A, Ceci F, D'Orlando G, Mercuri M, Alderisio A, Perretta L, Carrino F, Sernia G, Greco E, Picchio M, Marino G, Goglia A, Trombetti A, De Pascalis B, Panella S, Bochicchio O, Bandini A, Del Re L, Longo F, Micera O (2011) PPH-01 versus PPH-03 to perform STARR for the treatment of hemorrhoids associated with large internal rectal prolapse: a prospective multicenter randomized trial. *Surg Innov* 18:241–247
- Boccasanta P, Venturi M, Roviato G (2011) What is the benefit of a new stapler device in the surgical treatment of obstructed defecation? Three-year outcomes from a randomized controlled trial. *Dis Colon Rectum* 54:77–84
- Ommer A, Rolfs TM, Walz MK (2010) Long-term results of stapled transanal rectal resection (STARR) for obstructive defecation syndrome. *Int J Colorectal Dis* 25:1287–1292

7. Jayne DG, Schwandner O, Stuto A (2009) Stapled transanal rectal resection for obstructed defecation syndrome: one-year results of the European STARR Registry. *Dis Colon Rectum* 52:1205–1212
8. Lenisa L, Schwandner O, Stuto A, Jayne D, Pigot F, Tuech JJ, Scherer R, Nugent K, Corbisier F, Espin-Basany E, Hetzer FH (2009) STARR with Contour Transtar: prospective multicentre European study. *Colorectal Dis* 11:821–827
9. Arroyo A, González-Argenté FX, García-Domingo M, Espin-Basany E, De-la-Portilla F, Pérez-Vicente F, Calpena R (2008) Prospective multicentre clinical trial of stapled transanal rectal resection for obstructive defaecation syndrome. *Br J Surg* 95:1521–1527
10. Boccasanta P, Venturi M, Stuto A, Bottini C, Caviglia A, Carriero A, Mascagni D, Mauri R, Sofo L, Landolfi V (2004) Stapled transanal rectal resection for outlet obstruction: a prospective, multicenter trial. *Dis Colon Rectum* 47:1285–1296
11. Boccasanta P, Venturi M, Salamina G, Cesana BM, Bernasconi F, Roviario G (2004) New trends in the surgical treatment of outlet obstruction: clinical and functional results of two novel transanal stapled techniques from a randomised controlled trial. *Int J Colorectal Dis* 19:359–369
12. Gravié JF, Lehur PA, Hutten N, Papillon M, Fantoli M, Descottes B, Pessaux P, Arnaud JP (2005) Stapled hemorrhoidopexy versus milligan-morgan hemorrhoidectomy: a prospective, randomized, multicenter trial with 2-year postoperative follow up. *Ann Surg* 242:29–35
13. Senagore AJ, Singer M, Abcarian H, Fleshman J, Corman M, Wexner S, Nivatvongs S (2004) Procedure for Prolapse and Hemorrhoids (PPH) Multicenter Study Group. A prospective, randomized, controlled multicenter trial comparing stapled hemorrhoidopexy and Ferguson hemorrhoidectomy: perioperative and one-year results. *Dis Colon Rectum* 47(11):1824–1836
14. Correa-Rovelo JM, Tellez O, Obregón L, Miranda-Gomez A, Moran S (2002) Stapled rectal mucosectomy vs. closed hemorrhoidectomy: a randomized, clinical trial. *Dis Colon Rectum* 45:1367–1374
15. Boccasanta P, Capretti PG, Venturi M, Cioffi U, De Simone M, Salamina G, Contessini-Avesani E, Peracchia A (2001) Randomised controlled trial between stapled circumferential mucosectomy and conventional circular hemorrhoidectomy in advanced hemorrhoids with external mucosal prolapse. *Am J Surg* 182:64–68
16. Ho YH, Cheong WK, Tsang C, Ho J, Eu KW, Tang CL, Seow-Choen F (2000) Stapled hemorrhoidectomy—cost and effectiveness. Randomized, controlled trial including incontinence scoring, anorectal manometry, and endoanal ultrasound assessments at up to three months. *Dis Colon Rectum* 43:1666–1675
17. Naldini G (2011) Serious unconventional complications of surgery with stapler for haemorrhoidal prolapse and obstructed defaecation because of rectocele and rectal intussusception. *Colorectal Dis* 13: 323–327
18. Wadhawan H, Shorthouse AJ, Brown SR (2010) Surgery for obstructed defaecation: does the use of the Contour device (Trans-STARR) improve results? *Colorectal Dis* 12:885–890
19. Boccasanta P, Venturi M, Roviario G (2007) Stapled transanal rectal resection versus stapled anopexy in the cure of hemorrhoids associated with rectal prolapse. A randomized controlled trial. *Int J Colorectal Dis* 22:245–251
20. Naldini G, Martellucci J, Talento P, Caviglia A, Moraldi L, Rossi M (2009) New approach to large haemorrhoidal prolapse: double stapled haemorrhoidopexy. *Int J Colorectal Dis* 24:1383–1387
21. Braini A, Narisetty P, Favero A, Calandra S, Calandra A, Caponnetto F, Digito F, Da Pozzo F, Marcotti E, Porebski E, Rovedo S, Terrosu G, Torricelli L, Stuto A (2013 Jan 20) Double PPH technique for hemorrhoidal prolapse: a multicentric, prospective, and nonrandomized trial. *Surg Innov.* PubMed PMID: 23339147
22. Stuto A, Favero A, Cerullo G, Braini A, Narisetty P, Tosolini G (2012) Double stapled haemorrhoidopexy for haemorrhoidal prolapse: indications, feasibility and safety. *Colorectal Dis* 14:e386–e389
23. Naldini G, Martellucci J, Moraldi L, Romano N, Rossi M (2009) Is simple mucosal resection really possible? Considerations about histological findings after stapled hemorrhoidopexy. *Int J Colorectal Dis* 24:537–541
24. Festen S, Molthof H, van Geloven AA, Luchters S, Gerhards MF (2012) Predictors of recurrence of prolapse after procedure for prolapse and haemorrhoids. *Colorectal Dis* 14:989–996
25. Pescatori M, Gagliardi G (2008) Postoperative complications after procedure for prolapsed hemorrhoids (PPH) and stapled transanal rectal resection (STARR) procedures. *Tech Coloproctol* 12:7–19
26. FDA (2012) General Hospital Devices and Supplies. *Surg Innov* 20: 553–558
27. Arroyo A, Pérez-Vicente F, Miranda E, Sánchez A, Serrano P, Candela F, Oliver I, Calpena R (2006) Prospective randomized clinical trial comparing two different circular staplers for mucosectomy in the treatment of hemorrhoids. *World J Surg* 30: 1305–1310
28. Giuratrabocchetta S, Pecorella G, Stazi A, Tego G, De Fazio M, Altomare DF (2013) Safety and short-term effectiveness of EEA stapler vs PPH stapler in the treatment of degree III hemorrhoids: prospective randomized controlled trial. *Colorectal Dis* 15:354–358
29. Dindo D, Hahnloser D (2013) Anal mucosectomy for haemorrhoids: should we start to speak Chinese? *Colorectal Dis* 15:e186–e189
30. Petersen S, Schinkel B, Jürgens S, Taylessani C, Schwenk W (2013) Impact of prolapse mass on Contour® Transtar™ technique for third-degree rectal prolapse. *Int J Colorectal Dis* 28:1027–1030
31. Martellucci J, Naldini G, Del Popolo G, Carriero A (2012) Sacral nerve modulation in the treatment of chronic pain after pelvic surgery. *Colorectal Dis* 14:502–507